

Solving Complex Treatment Challenges

Increasing Occlusal Vertical Dimension via Full-Arch Rehabilitation



Richard Winter, DDS

INTRODUCTION

Patients often present for treatment with complex issues that can be multifactorial in nature. The skeletal, dental, periodontal, anatomic, and neurosensory factors can often be misconstrued as one isolated problem set. The patient is usually concerned with the main issues of pain and cost; arguably 2 of the most motivating factors in seeking and accepting treatment.

This article is a case study of a patient with a Class II Division 2 malocclusion, severe periodontal disease, and a painful occlusion. The journey undertaken to alleviate her pain led to a treatment plan of full-arch implant rehabilitation that successfully treated her temporomandibular joint (TMJ) and occlusal pain while providing the aesthetic outcome that she desired.

CASE REPORT

Diagnosis and Treatment Planning

This patient (Figure 1) presented with acute pain from chewing, as she bit into her incisive papilla every time that she closed into centric occlusion. In addition, she suffered from chronic TMJ pain that negatively affected her overall outlook, leading her to many dentists who proposed strictly dental prosthetic plans that involved replacing crowns to solve her problems. While this modality may have achieved some level of success, having generalized severe periodontitis present may have limited the longevity of any such solution.

The mandibular incisors occluded with her incisive papilla (Figure 2), and indentations from occlusal traumatism were present with mucosa that was denuded, ulcerated, and painful. The lack of anterior coupling, together with advanced (type IV) periodontal disease, led to super-eruption of the mandibular teeth. The curves of Spee and Wilson were uneven and further demonstrated the lack of occlusal harmony (Figure 3).

Records taken included study models, bite registrations at open- and closed-vertical positions, a face-bow transfer, photographs, a CAT scan, and a diagnostic wax-up.

The decision was made to edentulate the maxilla with socket preservation; use an inter-




Figure 1. Preoperative full-facial photo.

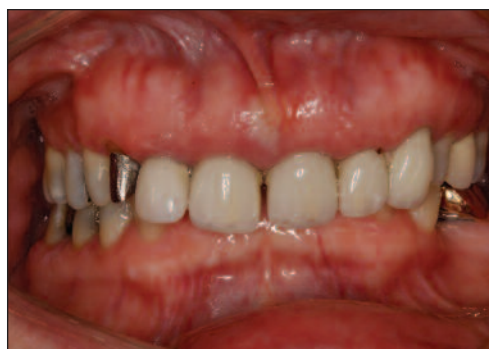

Figure 2. Retracted preoperative photo showing Class II, Division 2 malocclusion.

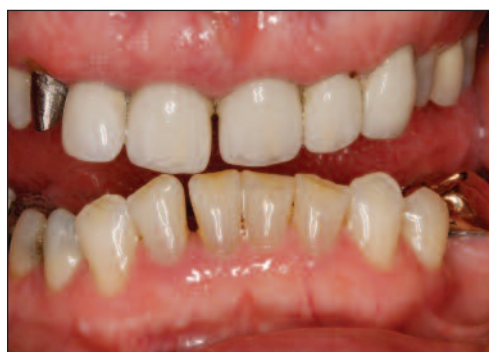

Figure 3. Retracted intraoral photo showing altered passive eruption, curve of Spee, and curve of Wilson.

im maxillary denture to work out her proper vertical dimension of occlusion (VDO); followed by full-arch implant rehabilitation. The DICOM image was electronically sent to

3DDX (3D Diagnostix) for reformatting. Within 24 hours, the image was delivered so it could be viewed and manipulated with SimPlant (Materialise Dental) software for implant selection, placement, and surgical guide development.

Clinical and Dental Laboratory Protocols

A sterile protocol was observed and the maxillary teeth were extracted with the use of periostomes, Luxators (JS Dental), and Physics Forceps (Golden Dental Solutions). This patient presented with significant buccal exostoses, so the utilization of an atraumatic extraction technique was desired to preserve the buccal shelf of bone. The Physics Forceps works like a Class I lever to extract the tooth in an occlusal direction with rotational forces in a gentle fashion (Figure 4). The maxillary edentulation was performed without complications, and the sockets were then filled with demineralized freeze-dried bone allograft with cortical cancellous chips (Puros [Zimmer Dental]), then covered with membranes (Mem-Lok [Bio-Horizons]) and sutured with 4-0 Vicryl (Salvin Dental). After healing, the ridge was smooth and keratinized gingiva was abundant (Figure 5).

A provisional denture, lined with tissue conditioner (Hydrocast [Kay-See Dental]), was delivered at the time of surgery. The tissue conditioner was changed monthly and resulted in a well-healed maxillary arch. The VDO was opened 5.0 mm, allowing mandibular tooth display (Figure 6).

The prescription of the maxillary complete denture included the desired overbite, overjet, and VDO; and, it was designed to be the prototypic restoration for the final porcelain bridge rehabilitation. The patient understood that the vertical dimension might need to be changed by either adding acrylic to posterior teeth or remaking the denture at a later date to ensure that she could accommodate the VDO change (Figure 7).¹

Within 24 hours of receiving her complete dentures, the patient reported a total cessation of all of her pain. Her joints felt good, and she could eat without biting herself.

continued on page 114

Solving Complex Treatment...

continued from page 112

The completed denture (approved for speech, aesthetics, comfort, and occlusion) was converted to a scanning appliance by bonding 8 BaSo₄ balls (3DDX) to the facial and lingual quadrants of the denture. Then, the patient was sent for a CBCT scan of her maxillary arch utilizing a dual-scan protocol (Figure 7). This protocol included scanning the patient with the denture in place along with a separate scan of the denture with the BaSo₄ balls, which would then be used to fabricate a surgical guide (Universal SurgiGuide Kit [Materialise Dental]) for implant placement. The 3DDX services include treatment planning, surgical guides, universal keys for osteotomy development, and performing a quality control check on the final SimPlant-based treatment plan. This can ensure a well-fitting surgical guide at time of surgery. After the scan was completed, the balls could simply be removed and cold sterilized for future use. The reformatted images were returned to the doctor and manipulated for proper implant size, distribution, and alignment. The images were finalized in the SimPlant program and uploaded to 3DDX for surgical guide fabrication and quality control checks (Figure 8).

The surgery was performed utilizing a sterile protocol. After performing 2 chlorhexidine rinses and anesthetizing the maxillary arch, the surgical guide was seated and the osteotomy sites were marked with a marking stick. Then, the tissue was trephined with the appropriate soft-tissue trephine drill and plugs removed. The guide was stabilized after making small labial osteotomies and attaching the guide with pushpins to the buccal aspect of the maxillary arch (Figure 9). Then, the tissue was trephined with the appropriate soft-tissue trephine drill and plugs removed.

The surgical keys were placed to sequentially enlarge the osteotomies and were used to accommodate the different sized surgical drills (Figure 10). After removal of the guide, the osteotomy placement and depth was complete, all done without raising a full-thickness flap (Figure 11). Implants (MIS Implants Technologies) were used for their unique condensing design and the use of single-use, sterile, stainless steel final sizing drills. These drills were used immediately prior to the placement of each implant. Healing caps were placed at the time of surgery (Figure 12) and the denture was relined with tissue conditioner.

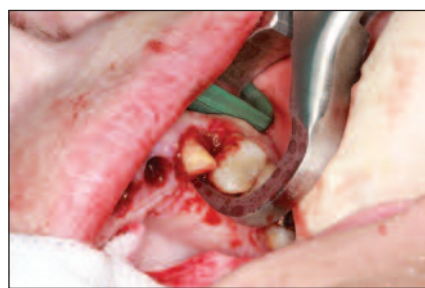

Figure 4. Physics Forceps (Golden Dental Solutions) being used.

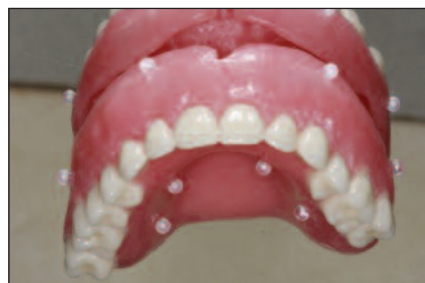

Figure 7. Approved denture with BaSo₄ balls (3DDX [3D Diagnostix]) for CBCT scans.

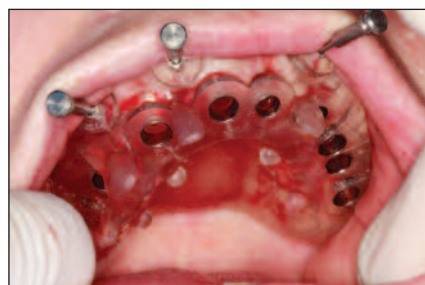

Figure 9. Surgical guide with pushpins inserted in maxilla.

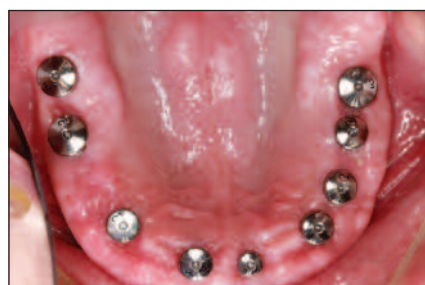

Figure 12. Occlusal view of all implants with healing abutments prior to impressing.

After 5 months, the tissues had healed nicely and the panoramic (PANOREX) and individual radiographs displayed no pathology (Figure 13). The removal of the per mucosal healing caps demonstrated adequate keratinized gingiva with excellent color and health during placement of the pre-machined abutments (Figure 14).

Placement of the snap cap impression copings (included in the Complete Prosthetic Kit [MIS Implants Technologies]) were used for primary impressions (Figure 15).

A pick-up impression of these snap caps was done with a vinyl polysiloxane (VPS) impression material (Aqua-sil Ultra Extra [DENTSPLY Caulk]) that provides up to one minute, 45 seconds of working time. The mouth removal

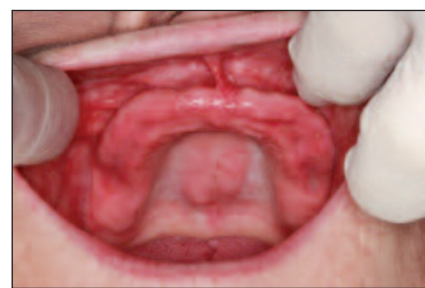

Figure 5. Maxillary arch after healing.

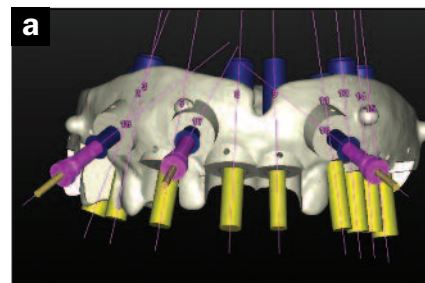


Figure 8a. 3DDX rendering of completed maxillary surgical guide.

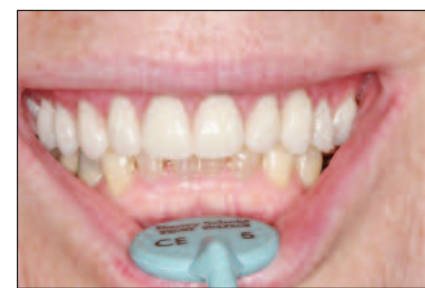

Figure 6. Retracted view of the first provisional denture showing the increased vertical dimension of occlusion.

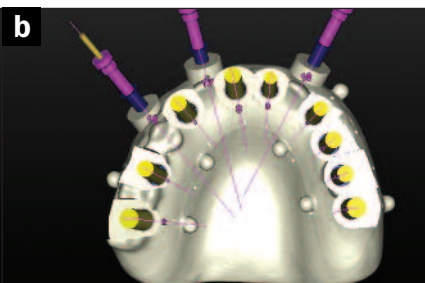


Figure 8b. Occlusal view of approved surgical guide.

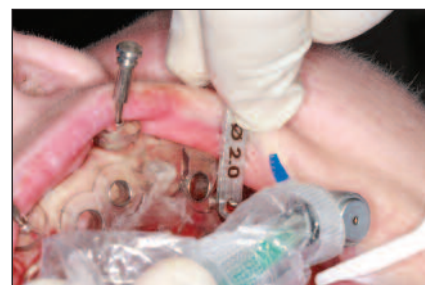

Figure 10. Placement of a 2.0-mm key for osteotomy development.

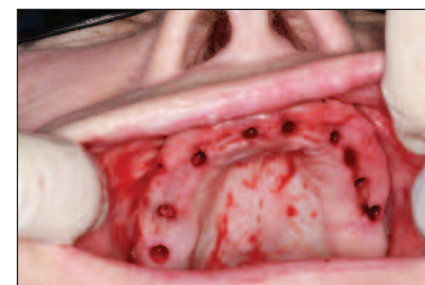

Figure 11. Appearance of maxillary arch after removal of surgical guide.

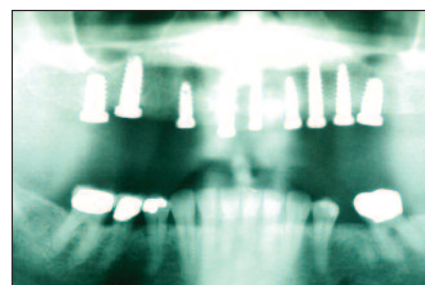

Figure 13. Panoramic radiograph (PANOREX) showing implant placement.

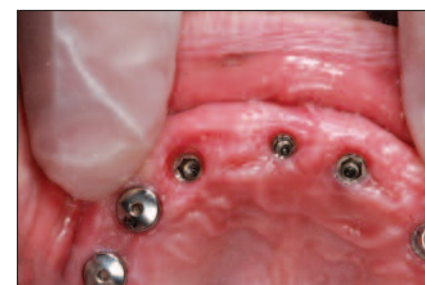

Figure 14. View of tissue during abutment connection.

time is 5 minutes, 45 seconds. To transfer the teeth shape, size, incisal edge position, and VDO to the laboratory at the same time, a unique impression transfer method was used.

The approved denture was modified by cutting 4 large openings in the palate of the denture so that impression material could be injected all the way through the denture to the palate. Then, a pick-up impression of the denture was made so the denture, and the contact with the palate in 4 large circular areas, was all picked up in this impression (Figure 16). When this denture impression was removed, the implant impression could be cross-mounted on to the denture model with the 4 palatal contact areas. The mushroom-like appendages that stick up

from the green and yellow VPS impression can be seen; these are used to orient the denture to the mounted implant coping impression (Figure 16). So the VDO, tooth size, shape, overbite, and overjet are all used by the lab team to fabricate the abutments. The abutment size, shape, and design are designed simultaneously with approved tooth size, shape, and locations.

Upon completion of the laboratory mounting, copings were fabricated to ensure that the abutments had been captured properly. Radiographs were taken to ensure all copings were seated and to see that the copings were designed with retentive elements for the secondary pickup. (Mr. Lezek Rapa, MDT, at Rapa Dental Ceramics, developed this coping

technique as well as the denture cross-mounting technique.) Pre-machined abutments were selected from the MIS abutment selection kit by the dental lab team. These were more cost effective than fabricating custom abutments, helping to keep the costs for the case within the patient's budget. Abutments were milled and delivered with abutment placement jigs (Figure 17).

The careful attention to all details allowed the lab team to provide the bridge superstructure for try-in and verification at the time of abutment delivery. The superstructure had the anterior sextant placed in wax (per doctor's prescription) to serve as a further check to verify that the aesthetics and phonetics were accurately transferred. The posterior bite registration was placed in Primotec pattern resin (Primotec USA) on the posterior occlusal surfaces to verify that concentric closure was occurring and the bite had been registered correctly (Figures 18a and 18b). It is notable that changes to the wax-up of the anterior 6 teeth were made with wax carving instru-

ments chairside to ensure that the overjet and overbite were indicative of that desired by the patient and doctor (Figure 18c). This superstructure (with the posterior occlusal relationship, anterior tooth size, shape, and position all verified) was locked into the mandibular arch with another bite registration of Blu-Mousse (Parkell). This would serve for remounting purposes and well as to protect the wax-up from fracture during transport.

The definitive bridge had been tried in its bisque bake form, and the patient had approved the aesthetics and phonetics. After final characterization and firing, a resin-based (implant) cement (Retrieve [Parkell]) was used to cement the bridge while allowing for the possibility of retrieving it at a later date, should the need arise. This resin-based long-term temporary cement has an inherent flexibility that allows for retrieval in an atraumatic fashion as its shear strength will allow for dislodgement (Figure 19).

The final photos display the countenance of the patient and nonverbal-ly verify the correct VDO. The patient

was aware that she would still have a Class II occlusion at the end of treatment and was absolutely fine with that, as long as her pain was eliminated. She could finally chew and have a smile that she was proud of, after years of being dissatisfied (Figure 20).

CLOSING COMMENTS

The bilateral balanced and lingualized occlusal schemes selected for this patient helped allow maxillo-mandibular freedom to decrease stress on her joints in working and nonworking movements, and in protrusion.² The shallow occlusal guidance and restoration of lost VDO further helped her achieve bone-braced condylar positions. This position was found by using her removable denture as the prototypic restoration and recreating it in a porcelain-fused-to-gold maxillary implant prosthesis. The subject of VDO and its resulting stability after altering this measurement are subject to debate. It is conjectured that VDO is a range, not a definitive number. The adaptive response of the patient, the occlusal biting scheme, and frequency

of resting contacts can help determine stability of a dentition after altering the VDO. Inevitably, it is the responsibility of the clinician to help the patient achieve a restorative result that falls within the envelope of an acceptable VDO.¹ The ability to find a comfortable joint position and a cosmetic improvement helped maintain a strong and favorable relationship during all phases of surgical and prosthetic rehabilitation. After seeing the before and after photographs (Figure 21), the patient remarked, "That picture shows me, and how I felt at the beginning and end of treatment...that photo tells the entire story!"♦

Acknowledgement

Dr. Winter would like to thank Mr. Leszek Rapa, MDT (Rapa Dental Ceramics, [727] 781-7885) for the innovativeness and laboratory excellence that he brings to Dr. Winter's cases.

References

- Gittelsohn GL. Vertical dimension of occlusion in implant dentistry: significance and approach. *Implant Dent.* 2002;11:33-40.
- Pound E. Let /S/ be your guide. *J Prosthet Dent.* 1977;38:482-489.

Suggested Reading

- Balshi TJ, Wolfinger GJ. Restoring lost vertical dimension of occlusion using dental implants: a clinical report. *Int J Prosthodont.* 1996;9:473-478.
- Fayz F, Eslami A. Determination of occlusal vertical dimension: a literature review. *J Prosthet Dent.* 1988;59:321-323.
- Harper RP. Clinical indications for altering vertical dimension of occlusion. Functional and biologic considerations for reconstruction of the dental occlusion. *Quintessence Int.* 2000;31:275-280.
- McGee GF. Use of facial measurements in determining vertical dimension. *J Am Dent Assoc.* 1947;35:342-350.
- Misch CE. Maxillary denture opposing an implant prosthesis. In: Misch CE, ed. *Contemporary Implant Dentistry*. 2nd ed. St. Louis, MO: Mosby; 1999.
- Misch CE, Bidez MW. Implant-protected occlusion: a biomechanical rationale. *Compendium.* 1994;15:1330-1344.
- Mohindra NK, Bulman JS. The effect of increasing vertical dimension of occlusion on facial aesthetics. *Br Dent J.* 2002;192:164-168.
- Orthlieb JD, Laurent M, Laplanche O. Cephalometric estimation of vertical dimension of occlusion. *J Oral Rehabil.* 2000;27:802-807.
- Silverman MM. Accurate measurement of vertical dimension by phonetics and the speaking center space. Part I. *Dent Dig.* 1951;57:261-265.
- Shanahan TEJ. Physiologic vertical dimension and centric relation. *J Prosthet Dent.* 1956;6:741-747.

Dr. Winter is a Master in the AGD and a Diplomate in the American Board of Oral Implantologists/Implant Dentists and in the International Congress of Oral Implantologists. He holds Fellowships in the Academy of Dentistry International and the International College of Dentists. He graduated from the University of Minnesota School of Dentistry in 1988. He has published numerous articles on implant and reconstructive dentistry emphasizing upgradeable dentistry and general dentistry as a specialty. He can be reached for lecture information via e-mail at rick@winterdental.com.

Disclosure: Dr. Winter has received material support from 3DDX.com and MIS Implants Technologies and received honoraria from Golden Dental Solutions, DENTSPLY Caulk, and Parkell.

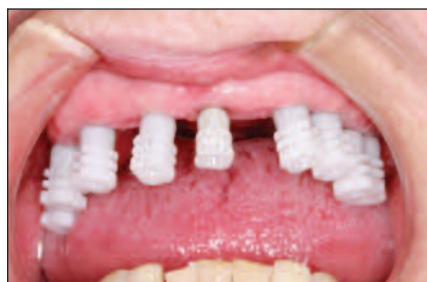

Figure 15. MIS snap cap impression copings in place (Complete Prosthetic Kit [MIS Implants Technologies]).

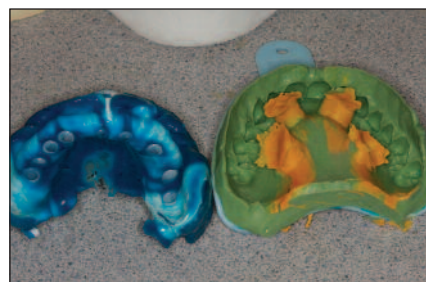

Figure 16. Aquasil Ultra Extra (DENTSPLY Caulk) pick-up impression of MIS snap caps and impression of denture with holes to facilitate cross mounting.

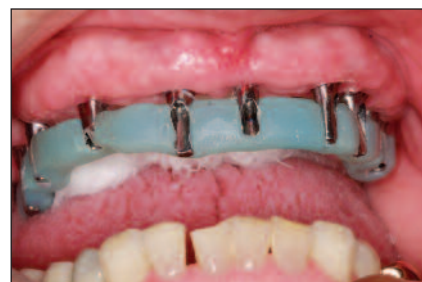

Figure 17. Abutments were milled and delivered with abutment placement jigs.

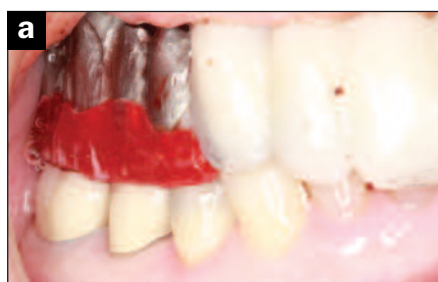

Figure 18a. Right lateral view of bridge framework with Primotec pattern resin (Primotec USA) and wax-up of anterior teeth; verifying aesthetics, phonetics, and the maxillo-mandibular relationship.

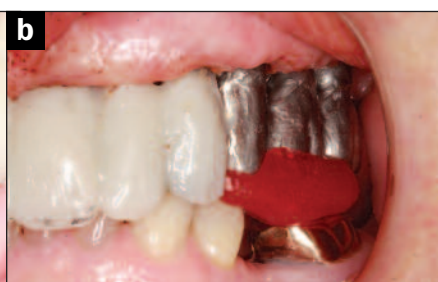

Figure 18b. Left lateral view of same.

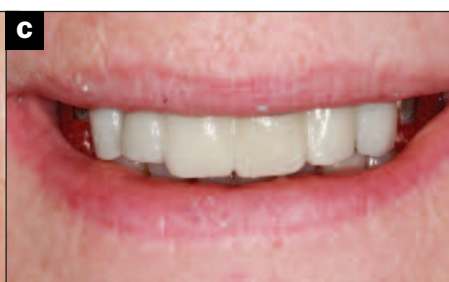

Figure 18c. Framework with white anterior wax-up to verify aesthetics and the incisal-edge position.

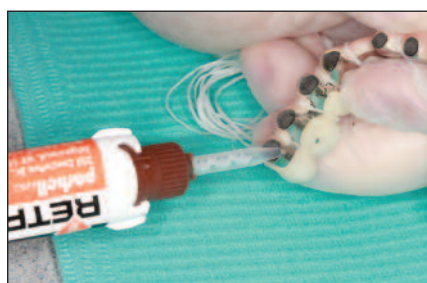

Figure 19. Cementation (Retrieve [Parkell]) of the definitive bridge.

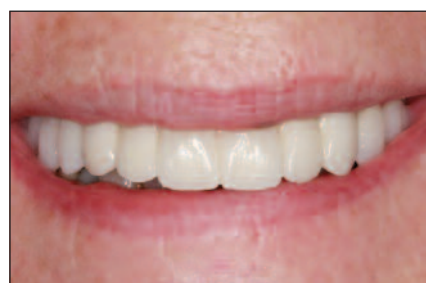

Figure 20. Postoperative smile.

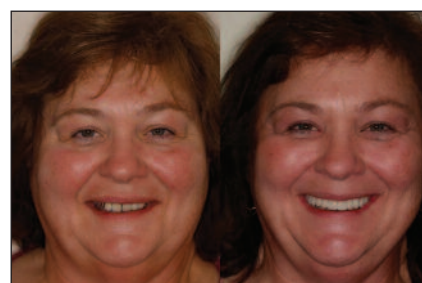

Figure 21. Pre-op and post-op photos.