

Upgradeable Dentistry, Part 4



Richard Winter,
DDS

This is part 4 of a 4-part article series. Part 3 of Dr. Winter's article was published in the November 2009 issue of *Dentistry Today* and can be found in our archived articles at dentistrytoday.com. This, and all future articles that are presented in multiple parts, will now be available to our readers for review in their entirety at our Web site, dentistrytoday.com. This is being done to help those readers who may have missed a portion of any multiple-part article, and will also facilitate the ability to review a complete article in its entirety for others.

In this final article of a 4 part series, the concept of "Upgradeable Dentistry" will be summarized by presenting the full circle from edentulism to becoming dentate. It is the author's hope that this series of articles will inspire dentists to become more involved in implant dentistry.

BACKGROUND

"Upgradeable Dentistry," as defined by this author is, "the dynamic and sequential improvement in a person's dental situation as defined by the patient; based on their emotional, financial, and social concerns. This concept applies to all aspects of dentistry and is not limited to dentures and implants, but can extend to bonding versus porcelain veneers, gold onlays versus extensive alloys, or any other procedure where a service is provided which improves comfort, provides a stable occlusion, and optimizes aesthetics over time.

Why Is Implant Dentistry Difficult for Some?

Patients want teeth. They all have egos, fears, financial worries, and preconceptions.

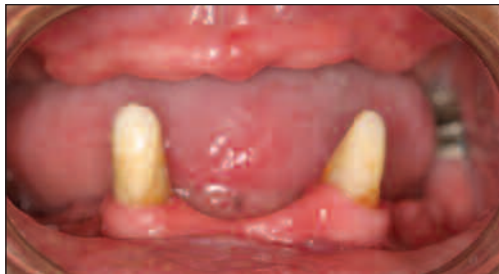

Figure 1. Case 1: A patient who has been wearing an upper denture and lower partial for more than 10 years. He has altered passive eruption of the canines, c-h bone in the mandibular anterior and posterior segments.

It is up to us to try and help patients achieve their goals. Implant dentistry can be difficult for dentists to become involved in for several definitive reasons. First, doctors may not fully understand the options available, treatment planning, bone height and width requirements, or the surgical costs involved. Second, dentists may not understand all of the steps needed, or what is involved from a fee standpoint, in order to competently complete the case. Third, they are often at the mercy of the referring specialist as to the type of implant system used, the overall

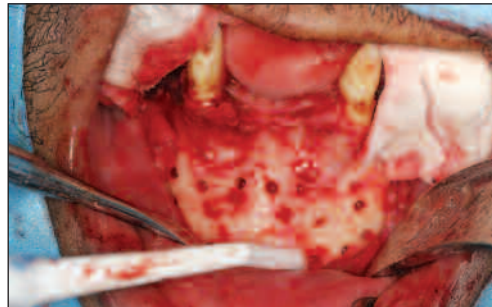

Figure 3. Outline of the donor site for symphysis grafting was performed so that sufficient bone could be grafted to allow for fixed, "FP-3" teeth.

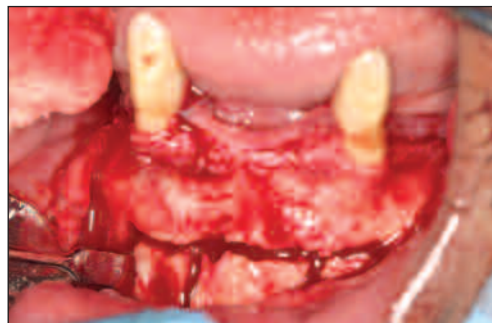

Figure 4. Outline form for the graft, avoids mental nerve involvement, and maximizes the harvest of autogenous bone—the gold standard for ridge augmentation.

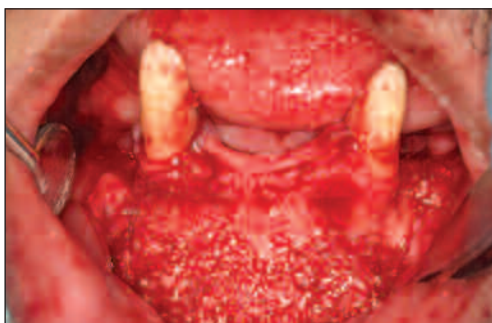

Figure 5. The defect is filled in with a combination of demineralized and mineralized freeze dried bone mixed with plasma rich proteins to allow the defect to fill in more rapidly.

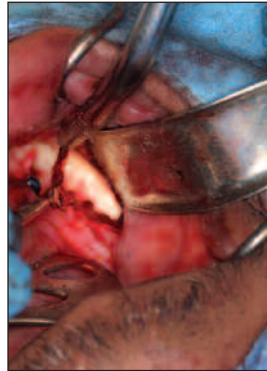

Figure 2. Harvest of the ramus was accomplished as part of an overall rehabilitation plan to augment the patient's mandible and maxilla.

treatment dollars available, and how they are allocated between the specialist and the referring dentist. Any of these topics could be elaborated upon in great detail, and that is why lectures, continuing education centers, books, Internet courses, etc, are all a part of acquiring this information.

Finding a Mentor

For the purposes of this article series, let us summarize these issues by recommending that you find a mentor who will help you learn what you don't

know to assist you in achieving success throughout the implant experience. In my case, I have found 2 highly experienced general practitioners with more than 20 years of experience each. They are willing to sit down with me and discuss Computerized Axial Tomography (CAT) scans, models, treatment plans, and finances so that we have a seamless integration of information to present to our patients.

CASE 1

A patient who had suffered from denture wear for many years came into our office (Figure 1). He experienced continual bone loss. C-h bone is visible, accentuated by the altered passive eruption of his mandibular canines. The concepts of "upgradeable dentistry" were discussed for years before the patient sought treatment. Upon delivery of his denture and partial, it was emphasized that these were to be considered temporary prostheses and that bone loss would continue from denture abrasion and disuse atrophy over time.

The patient desired a fixed restoration and he opted for grafting to augment his deficient ridges with implant placement as needed to achieve "fixed teeth." In Figure 2 we can see the outline of the ramus where bone was harvested for augmentation of his deficient mandible and maxilla. Figure 3 shows the outline of the donor site from a symphysis graft, where the maximum amount of bone could be removed without violating important anatomical landmarks. In the next photo (Figure 4), we can see the completed cut to connect the outlined bone segment. It was removed and fixated with titanium bone screws to areas requiring implant placement.

The defect was then filled with deminer-

continued on page ##

Upgradeable Dentistry, Part 4

continued from page

alized freeze-dried bone and mineralized bone allograft (Grafton and Minneross respectively) with plasma rich proteins (Figure 5).

Placing the implants (Figure 6), according to the pre-approved wax-up and denture, allowed for restoration driven implant placement and helped us achieve an optimal A-P spread. The 9 implants (BioHorizons) were aligned and a ball top screw was placed in their 3-in-1 abutments so a preliminary surgical impression could be taken to begin our laboratory planning.

Nine Atlantis abutments were fabricated and delivered after suitable healing to aid in placement of our fixed prosthesis (Figure 7). The decision to create a cemented hybrid restoration versus fixed bridgework was due to the extensive height of the final prosthesis, reparability of the prosthesis, and the relative costs of the final prosthesis (had high noble gold been chosen for the restoration).

Sometimes the treatment can involve placement of the implant infrastructure with a simple attachment denture until a patient's finances will allow them to upgrade their prosthesis to a fixed partial denture. In the treatment planning process, we must allocate funds based upon funds available. Dr. Misch often asks his patients how much they can invest now and over the next few years. The ability to openly discuss finances empowers us to help our patients. If this is a "one-shot deal" and patients don't have resources left, we are limited as to our initial treatment regimen. On the other hand, if we have a built-in staging, we can often load a patient's treatment to provide more infrastructure, decrease surgical costs, increase discounts by providing more foundational dentistry at the beginning of treatment. Sometimes the dentists I work with will provide extra implants at time of surgery at no or minimal costs in order to allow us to more easily retain bone for a future rehabilitation.

In Figure 8 we see patient No. 1 after his lower arch is restored. He has lingualized occlusion. A break in the cemented hybrid prosthesis at the mental foramen was included in the prosthetic design to allow for mandibular flexion/torsion to occur in a nonlimited fashion.

In Figure 9, one can observe the upper denture opposing the mandibular cemented bridge which allowed our patient's diet to improve substantially. The patient's wife has reported needing "a second job to pay the food

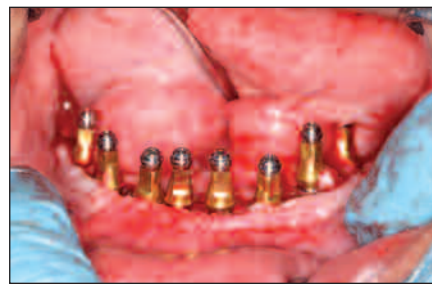

Figure 6. Nine implants (BioHorizons) were placed with an optimal A-P spread in the grafted mandibular arch to provide for sufficient support for a cemented hybrid restoration.

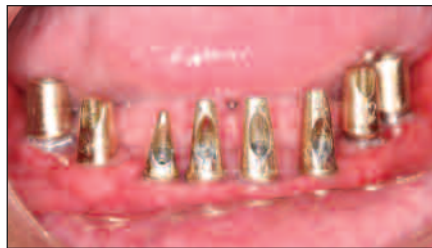

Figure 7. Abutments (Atlantis) were fabricated and cast to allow for more prosthesis support than standard abutments would have provided.

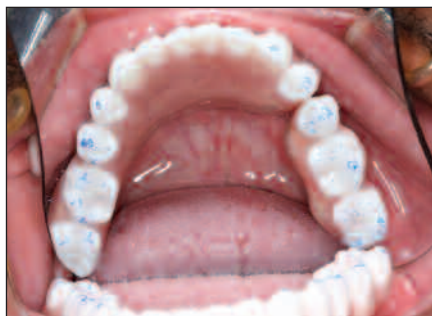

Figure 8. The occlusal view of the finished hybrid prosthesis demonstrating the lingualized occlusion and a break at the mental foramen. Splinting a complete lower arch would not allow for mandibular torsion/flexion, so a full prosthesis needs to be separated at one of the mental foramina.

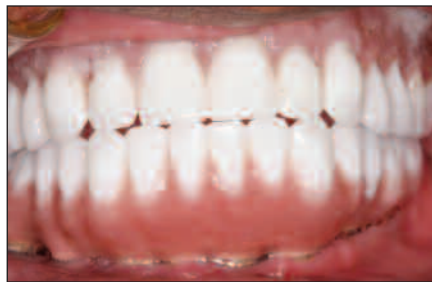

Figure 9. The completed, delivered mandibular fixed restoration. Lingualized occlusion with the interim upper denture can be visualized.

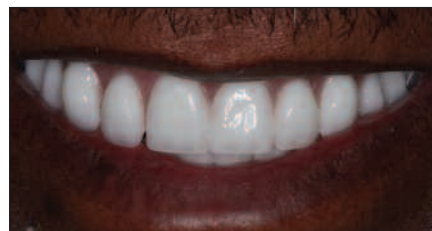

Figure 10. Smile line display of upper denture with the cemented lower hybrid restoration.

ills now!" (There are openings for supperflous to pass under the bridge.)

We see the final smile (Figure 10) of the upper denture opposing the implant restoration. This denture is covering a grafted maxilla which has 9 implants awaiting uncover and a

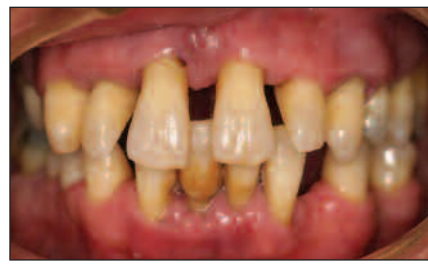

Figure 11. Case 2: The patient presented with severe periodontal disease necessitating full edentulation with fixed implant restorations in both arches. Several teeth were maintained for long-term abutments for provisionalization.

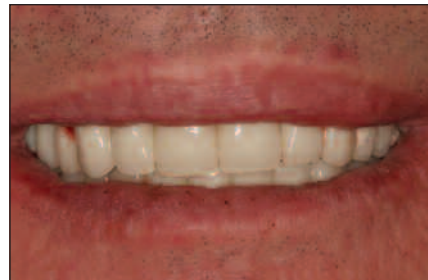

Figure 12. Case 2: The delivered temporary restorations (BioTemps [Glidewell Dental Laboratories]) placed at the time of implant surgery and partial edentulation.

full-arch fixed bridge.

CASE 2

The degree of aesthetic improvement can be demonstrated to patients before treatment is undertaken by utilizing diagnostic wax-ups, cosmetic imaging, or laboratory-fabricated provisionals. For this patient, we used imaging and a diagnostic wax-up to educate our patient. As a result, a man who was extremely anxious and dental phobic from fear of being without teeth was gradually transitioned to full-mouth restorations once we ensured his ability to have a fixed temporary during treatment. In this patient, we see multiple diastemas, splayed maxillary anterior and mandibular anterior teeth from class 4 mobility, and a traumatic occlusion (Figure 11).

The bicusps and canines were stable and solid enough to retain provisional restorations. After anesthesia, the teeth to be retained were prepared for crowns and were used to support the provisional, keeping pressure off of the implants that were placed at time of extraction.

Figure 12 shows the patient's smile after edentulation of all teeth (except for pier abutments), and cementation of his provisionals. This case highlights the importance of understanding what the patient wants and needs during treatment. Some patients are afraid of being without teeth during treatment. If teeth can't be used for support of a temporary, then often transitional implants can be placed to support a provisional bridge during healing.

Then the mini-implants can be removed and the osseointegrated implants can have temporary abutments to support a new temporary at phase 2 surgery.

CASE 3

In the next patient, Figures 13 to 15 shows the frontal and right/left lateral views of a patient with severe AAP 4 periodontitis. He was a chronic smoker. He had been educated about bone loss years earlier, when upon referral, he was told by a specialist that a hip graft was the only way he could achieve implants for a fixed restoration. After careful evaluation and imaging with the implant surgeon, it was decided that the patient could be treated with a combination of sinus augmentation and ridge spreading technique to provide sufficient bone for the 9 implants to be placed.

The provisionals (or prototype restorations) were fabricated along with a complete upper denture, allowing for multiple options at time of surgery to temporize the patient. This patient expected a removable implant overdenture. After evaluating the aesthetics, speech, and comfort of his fixed temporaries (Figure 16), the patient opted to "upgrade" to a fixed

continued on page ##

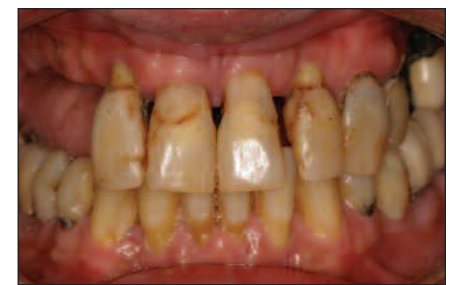

Figure 13. Case 3: Generalized severe periodontitis frontal view. The patient is undergoing segmental full mouth rehabilitation.

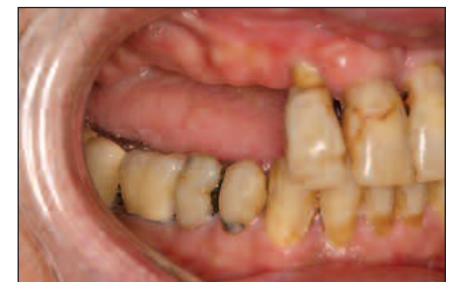

Figure 14. Right lateral view shows extensive bone loss secondary to chronic periodontitis.

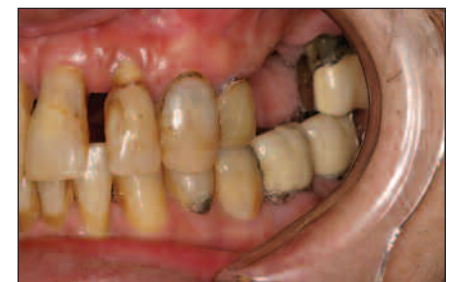

Figure 15. Left lateral view of patient demonstrates tooth loss, cross bite, and spacing as a result of increased mobility of all teeth.

Upgradeable Dentistry, Part 4...

continued from page

implant bridge. It should be noted that this patient had planned financially and accepted treatment for full-mouth rehabilitation, and thus far, has completed his maxillary and mandibular right restoration.

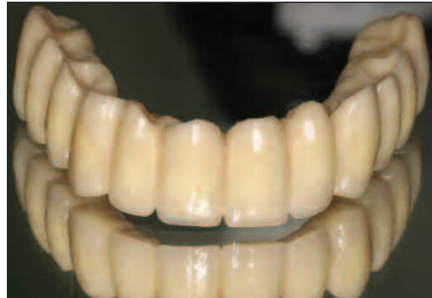

Figure 16. Laboratory fabricated temporary restoration (Biotemps) for placement at first surgery.

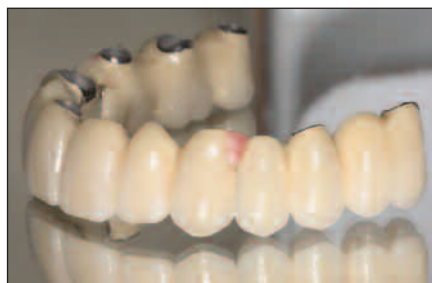

Figure 17. Final fixed restoration FP2. Incisal edge position, aesthetics, phonetics, and function were evaluated with the provisional prosthesis.

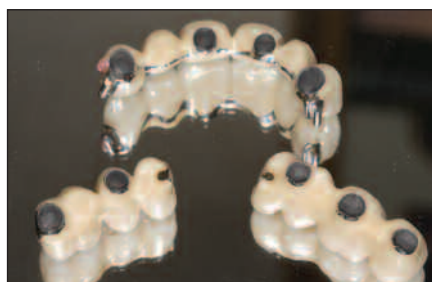

Figure 18. View of fixed bridgework in 3 pieces with 2 dovetails. This design may aid in retrievability. (Note: There was sufficient retention that allowed us to break the prosthesis up.)

The completed bridgework, as seen in Figures 17 and 18, shows the 3-piece porcelain-fused-to-gold restorations which have been created with dovetails at the distals of each canine. The use of Tatum implants and their abutments (*prepared intraorally*) have helped to keep the costs of this case within reach for the patient. Laboratory bills can escalate quickly when we include custom abutments, soft-tissue models, custom anterior guide tables, high noble gold, pink porcelain fabrication, model work, implant components, custom milling, etc. So, we must evaluate costs of not only surgical sides of treatment, but the costs of the prosthesis, profit needs, and overhead expenses. Then, we can make choices with regard to abutment selection, prosthesis type,

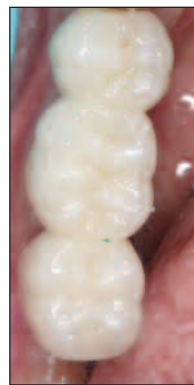

Figure 19. The segmental rehabilitation continued with placement of 3 implants in the patient's lower right quadrant to remove loose and painful teeth.

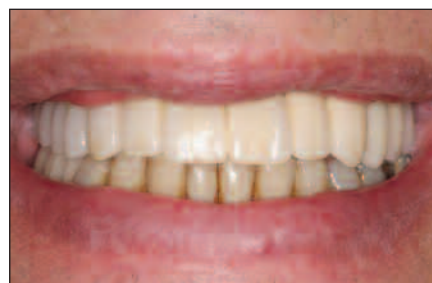

Figure 21. Completed maxillary and mandibular right reconstruction. The crown height has been corrected to change the prosthesis from FP-3 (long teeth with excess porcelain), to FP-1 normal tooth sizing. This patient was able to reverse time aesthetically.

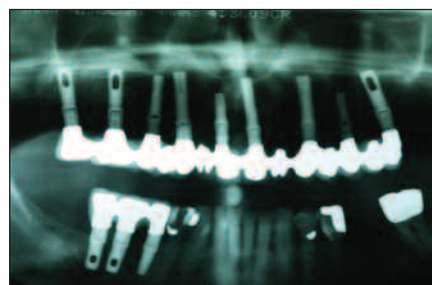


Figure 22. Panoramic radiograph of the patient's reconstruction to date. This patient will require continued extraction and implant rehabilitation according to his desires and budget.

who purchases the implant components, etc, to make the case viable.

The use of premier dental laboratories can be invaluable in helping guide the implant dentist, reducing the time and frustration associated with the improper fit of frameworks, and the overall beauty of the final prosthesis. However, that being said, a dentist should be aware of all fees related to the successful delivery of a case before beginning treatment so that surprises do not lead to disappointment.

In Figure 19 we see the 3-implant-supported bridge in the patient lower right quadrant. It is of note that implant crowns should have a narrower occlusal table to decrease force factors on the prosthesis. In addition, they should have flatter occlusal mor-



Figure 20. Final smile of implant supported bridges.

phology if lingualized occlusion is to be constructed. The patient in his final photos (Figures 20 and 21) is stable and extremely happy to have had his long teeth shortened. We can see the 9 Tatum abutments, which were prepared intraorally prior to delivery of the bridge. In the panoramic radiograph (Figure 22), one can observe a sufficient number of implants, and

proper height and A-P spread to support his maxillary and mandibular implant bridges.♦

Acknowledgment

Special thanks go out to Dr. John Werwie for his surgical expertise and mentorship as demonstrated in case 1. I also wish to thank Dr. Leonard Machi for his surgical excellence and mentorship as demonstrated in case 2 and 3. The concepts I discuss wouldn't be possible without the outstanding commitment to excellence I have been afforded through working with these outstanding clinicians. I would like to thank Burbank Dental Lab, Rapa Dental Ceramics, Nu-Life Dental Lab, Valley Dental Arts, and Glidewell Dental Laboratories for the beautiful dental work as seen in this series.

Continuing Education Available

For an accelerated introduction into implant dentistry, courses are available from various organizations for those interested (AAID, ICOI, Misch International Implant Institute, Anthony Sclar's and Pikos' courses). Seeing lecturers ranging from Leonard Machi, Carl Misch, Hilt Tatum, Jack Turbyfill, Paul Homoly, and Ara Nazarian can all add to your perspectives in implant and rehabilitative dentistry. National meetings such as the AGD, AAID, ICOI are all great beginning steps for beginning your journey.

Suggested Readings

- Adell R, Lekholm U, Rockler B, et al. A 15-year study of osseointegrated implants in the treatment of the edentulous jaw. *Int J Oral Surg.* 1981;10:387-416.
- Misch CE. Treatment options for mandibular full arch implant-supported fixed prostheses. *Dent Today.* August 2001;20:68-73.
- Nazarian A. How to increase case acceptance. *Dent Today.* 2007;26:136-137
- Nazarian A. An efficient approach to full-mouth reconstruction of the apprehensive patient. *Dent Today.* 2003;22:70-73.
- Sethi A, Kaus T. Maxillary ridge expansion with simultaneous implant placement: 5-year results

- of an ongoing clinical study. *Int J Oral Maxillofac Implants.* 2000;15:491-499.
- Simion M, Baldoni M, Zaffe D. Jawbone enlargement using immediate implant placement associated with a split-crest technique and guided tissue regeneration. *Int J Periodontics Restorative Dent.* 1992;12:462-473.
- Tatum OH. The omni implant system. In: *Hardin J. Clark's Clinical Dentistry.* 5th ed. Philadelphia, Pa: JB Lippincott; 1984.
- The completely edentulous mandible: treatment plans for fixed restorations. In: Misch CE. *Contemporary Implant Dentistry.* 3rd ed. Philadelphia, Pa: Elsevier; 2008: 314-327.
- Treatment plans related to key implant positions and implant number. In: Misch CE. *Contemporary Implant Dentistry.* 3rd ed. Philadelphia, Pa: Elsevier; 2008: 147-160.
- Winter R. Upgradeable dentistry, part 1. *Dent Today.* June 2009;28:82, 84, 86-87.
- Winter R. Upgradeable dentistry, part 2. *Dent Today.* July 2009;28:97-98, 100.
- Winter R. Upgradeable dentistry, part 3. *Dent Today.* Nov 2009;28:94-99.
- Wright PS, Glantz PO, Randow K, et al. The effects of fixed and removable implant-stabilised prostheses on posterior mandibular residual ridge resorption. *Clin Oral Implants Res.* 2002;13:169-174.

Dr. Winter is in private practice and lectures on the topic of "Upgradeable Dentistry." He also teaches a continuum entitled *Recession Proofing Your Practice in Today's Economy* with Dr. Ara Nazarian. He can be reached at (414) 464-9021, via e-mail at rick@winterdental.com, or by writing him at Hampton Dental Associates, 5323 W. Hampton Ave. Milwaukee, WI 53218.

Disclosure: Dr. Winter reports no conflicts of interest.

Other articles linked in this series can be found on dentistrytoday.com